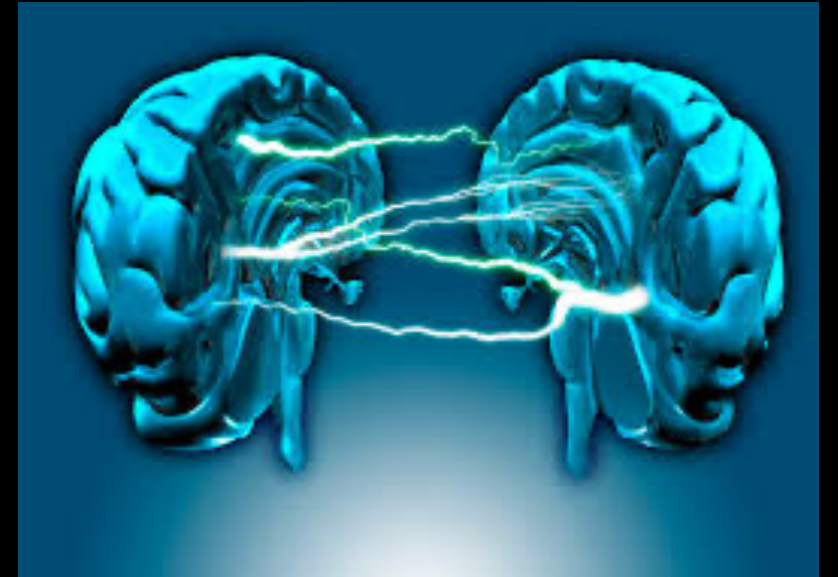


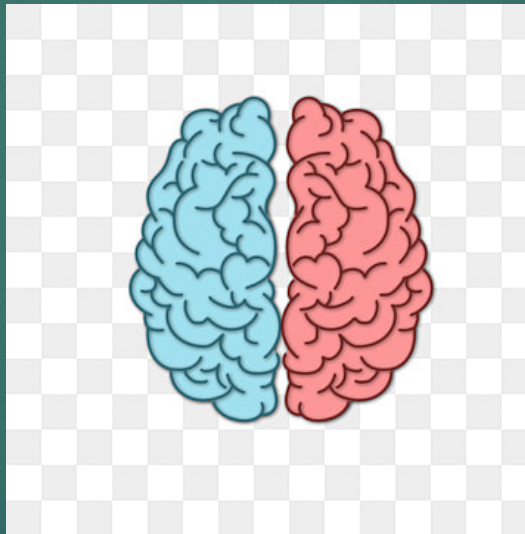
The Neural Organization of Language: Evidence from Sign Language Aphasia

BY: GREGORY HICKOK, URSULA BELLUGI AND EDWARD S. KLIMA



Language asymmetry: left vs right hemisphere

- ▶ The left-hemisphere's (LH) dominance for language is well-established.
- ▶ HOWEVER the basis of this asymmetry is still a matter of debate!
- ▶ There have been debates on the left hemisphere...
 - ▶ Some have said it is for: LH has neural systems for processing linguistic information
 - ▶ Others have said: it is for a more domain-general process, or set of process.



- ▶ There are 2 Principle Candidates proposed for a domain-general basis for language asymmetry:
 - ▶ (1) Processing of rapidly changing temporal information
 - ▶ (2) controlling the articulation of complex motor sequences
- ▶ Processing language involves neural mechanisms such as these to some extent
 - ▶ Evidence that suggests than an impairment in fast term temporal processing or articulation of motor commands can affect aspects of language performance




Sign language (SL) as a natural human language

- ▶ The data comes from studies of deaf individuals who have unilateral brain lesions, and primary means of communication is American Sign Language (ASL)
- ▶ This group provides a means to examine neurobiology of a natural, highly structured human language.
 - ▶ (a) Spatially contrasts at the lexical level
 - ▶ (b) Spatially nested morphology
 - ▶ (c) Spatially organized syntax
- ▶ SL of the deaf are formal, highly-structured linguistic systems
- ▶ SL emerged independently of the language used among hearing individuals in the surrounding community. ASL & British language: mutually comprehensible
- ▶ ASL has developed as a fully autonomous language with grammatical structuring at the same levels as spoken language and with similar kinds of organized principles

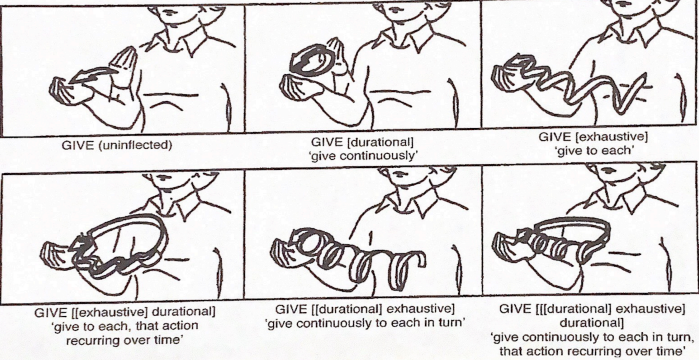
Box 1. Sign language as a natural human language

A Spatial contrasts at the lexical level



'Summer' 'Ugly' 'Dry'


B Spatially nested morphology



GIVE (uninflected) GIVE [durational] 'give continuously' GIVE [exhaustive] 'give to each'

GIVE [[exhaustive] durational] 'give to each, that action recurring over time' GIVE [[durational] exhaustive] 'give continuously to each in turn' GIVE [[[durational] exhaustive] durational] 'give continuously to each in turn, that action recurring over time'

C Spatially organized syntax



'mother/index,' 'force,' 'give,' 'box'

The Signs of Aphasia

- ▶ In deaf life-long signers, the LH is dominant for comprehension and production of signed language.
- ▶ In these studies..
 - ▶ Left hemisphere damage (LHD) signers presented with disruptions in various aspects of their signing ability (aphasia),
 - ▶ Right hemisphere damage (RHD) signers were non-aphasic
- ▶ Types of Sign language deficits
 - ▶ Paraphasic Errors
 - ▶ Fluent and non fluent aphasias
 - ▶ Naming
 - ▶ Agrammatism
 - ▶ A case of 'sign blindness'
 - ▶ Double dissociation between sign language ability and non-linguistic spatial cognitive ability.



CASE STUDIES: (1) Paraphasic Errors

- ▶ What are Paraphasic Errors??
 - ▶ a hallmark of aphasia is the presence of Paraphasic errors in language production.
- ▶ Several types of Paraphasic errors occur to varying degrees in different types of aphasia. These include..
 - ▶ **Literal or phonemic** paraphasia's in which errors are made in the sound pattern of words; E.g. 'tagle' for 'table'
 - ▶ **Verbal or semantic paraphasia's** in which a semantically related word is substituted for the target; E.g. 'uncle' for 'brother'
 - ▶ **Pragmatic paraphasia's** in which inappropriate or neologistic words or morphemes are selected during running speech.

Similar range of Paraphasic errors have been made with LHD singers. Some examples of phonemic and paragrammatic are shown in the next slide

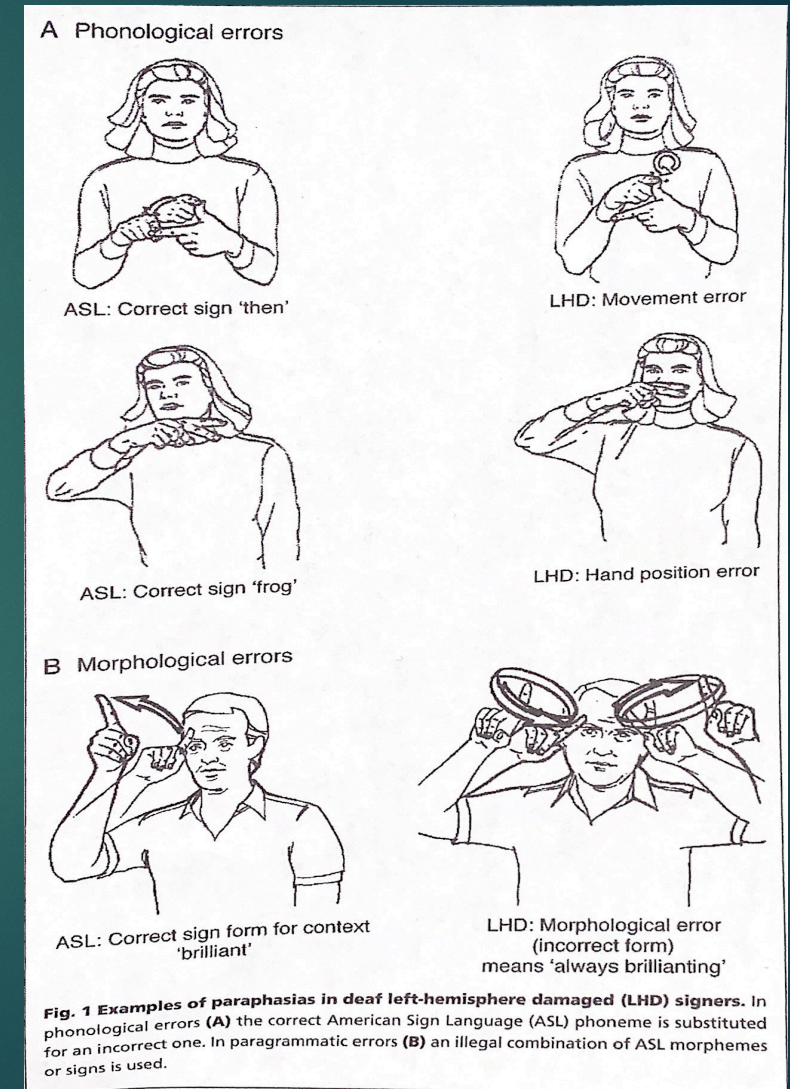
CASE STUDIES: Paraphasic Errors

- ▶ Phonemic errors:

- ▶ Figure A: shows a substitution of one ASL phoneme for another

- ▶ Pragmatic errors:

- ▶ Figure B: represents an illegal combination of ASL morphemes, the root sign 'brilliant' combined with the grammatical inflection that conveys a meaning similar to 'characteristically'.
- ▶ Errors like these are common in LHD signers, not in RHD signers.



CASE STUDIES: Fluent aphasia (FA) and non-fluent aphasias (NFA)

▶ (2) **Fluent aphasia and Non fluent Aphasias**

- ▶ The distinction between FA and NFA types is prominent in aphasia research and appears to be a fairly robust dichotomy. This has been observed in sign language aphasia (SLA).
- ▶ **Broca's-aphasia-like syndrome:** partial loss of the ability to produce language (spoken, manual, or written), although their comprehension generally remains intact.
 - ▶ One subject presented with a BAL syndrome, her lesion involved most of the left lateral frontal lobe.
 - ▶ A contrasting case had more of a posterior lesion. He was able to string together sequences of several signs effortlessly, but produced frequent Paraphasic errors & several pragmatic errors.

CASE STUDIES: Naming & Agrammatism

(3) Naming

- ▶ A virtually universal symptom of aphasia is a difficulty in retrieving words.
- ▶ A deficit usually revealed when subjects are asked to provide a name of pictured objects or actions.
- ▶ Experiment: 32-item naming test on RHD subjects correctly named an average of 31.1 items.
 - ▶ 63% scored below RHD range.
 - ▶ LHD subjects with non-perisylvian or subcortical lesions scoring below RHD increased by 80%

(4) Agrammatism

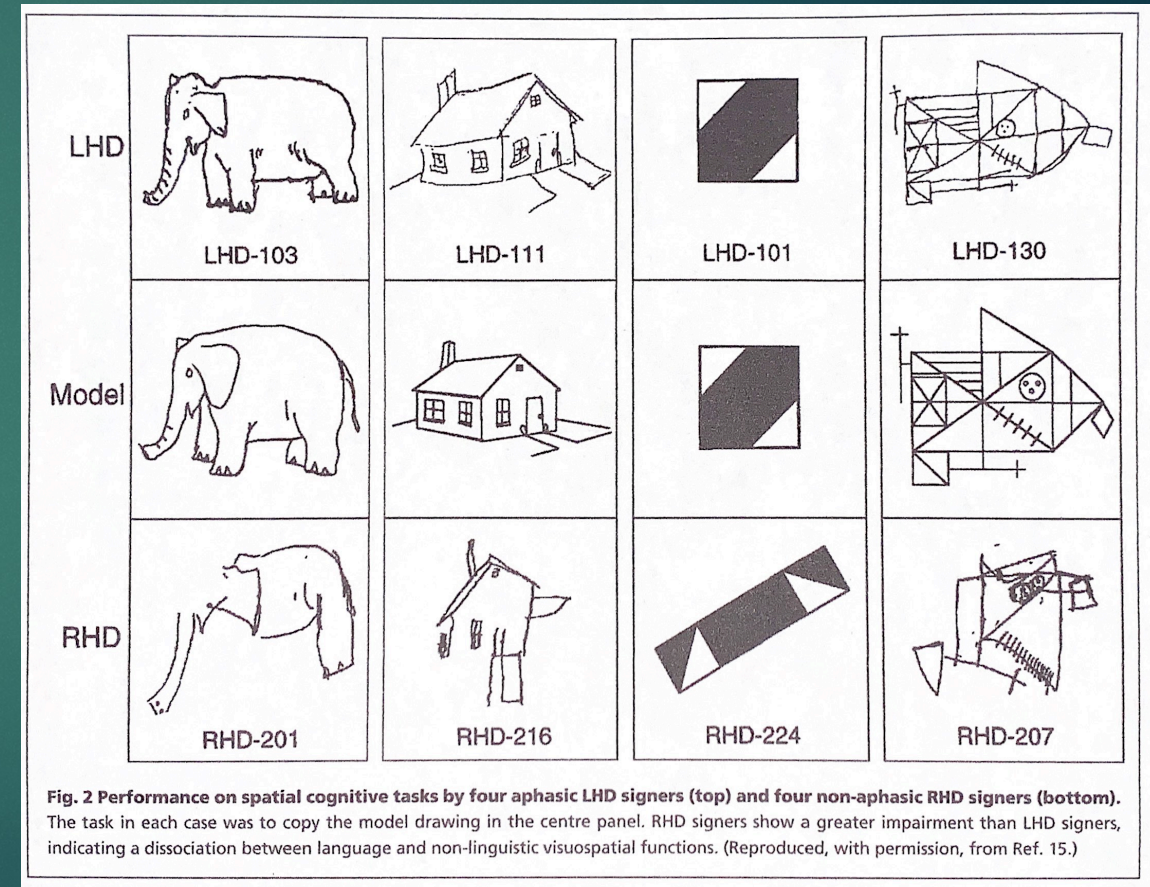
- ▶ common feature of aphasia produced by anterior left perisylvian lesions.
- ▶ Tendency to omit grammatical function morphemes in speech
- ▶ Subject with BAL syndrome was severely non-fluent, lacked syntactic and morphological markings required in ASL.

CASE STUDIES: 'SIGN BLINDLESS'

- ▶ (5) Sign Blindness:
 - ▶ Pure word blindness or alexia without agraphia, is well documented in literature
- ▶ Patients with this disorder have normal spoken and heard capacity, are able to write, but cannot read even their own writing.
- ▶ Language areas are preserved, allowing normal production, comprehension and writing, but these areas are isolated from visual input.
- ▶ Deaf signer that was recently reported had such a lesion and was alexic as expected. Would her signing be similarly affected? The answer is YES!!
 - ▶ Her signing was fluent and grammatical, yet her comprehension was profoundly impaired. She could not follow a simple one-step ASL command.
- ▶ Visual object recognition, was unimpaired.
 - ▶ Patient was essentially blind for sign language as a result of her left medial occipito-temporal lesion that isolated the LH language systems from visual information (interesting!!!)
- ▶ This case was in favor of the LH being dominant for ASL!!! This shows that the RH by itself has little capacity to process signed language beyond rudimentary single-sign comprehension

CASE STUDIES: Double dissociation between sign language ability and non-linguistic spatial cognitive ability

- ▶ (6) Double Dissociation: determines whether deficits in sign language processing are simply a function of deficits in general spatial cognitive ability, standard measures of visuospatial cognition have been administered.
- ▶ The image to the right shows dissociations between language and non-linguistic visuospatial abilities.
- ▶ Subjects were asked to draw the model drawing in the center of the panel.
 - ▶ RHD signers had a harder time replicating the image than LHD signers.



GROUP STUDIES: Language assessment

- ▶ Participants:
 - ▶ 13 LHD & 10 RHD signers
- ▶ Method:
 - ▶ ASL- adapted version of the Boston Diagnostic Aphasia Examination
 - ▶ Studied each subjects competence in several basic aspects of language use: production, comprehension, naming and repetition.
- ▶ Results:
 - ▶ This group confirmed the hypotheses of LH being dominant for sign language.
 - ▶ LHD signers performed significantly worse than RHD signers on all measures.
 - ▶ The differences were even for subjects who were deaf from birth and were exposed to ASL prelingually (3 RHD, 3 LHD)

GROUP STUDIES: Non-linguistic spatial cognitive assessment

- ▶ As aforementioned Double-dissociation has been documented between sign languages deficits and deficits in non-linguistic visuospatial abilities.
- ▶ The visuospatial abilities that were assessed in that work involved relatively gross, global disruptions, of that are typically associated with RHD.
- ▶ The data may show separability between language visuospatial function.
- ▶ BUT the question of more subtle visuospatial deficits underline sign lang deficits was not addressed.
 - ▶ A recent experiment addressed this issue (see on next slide)

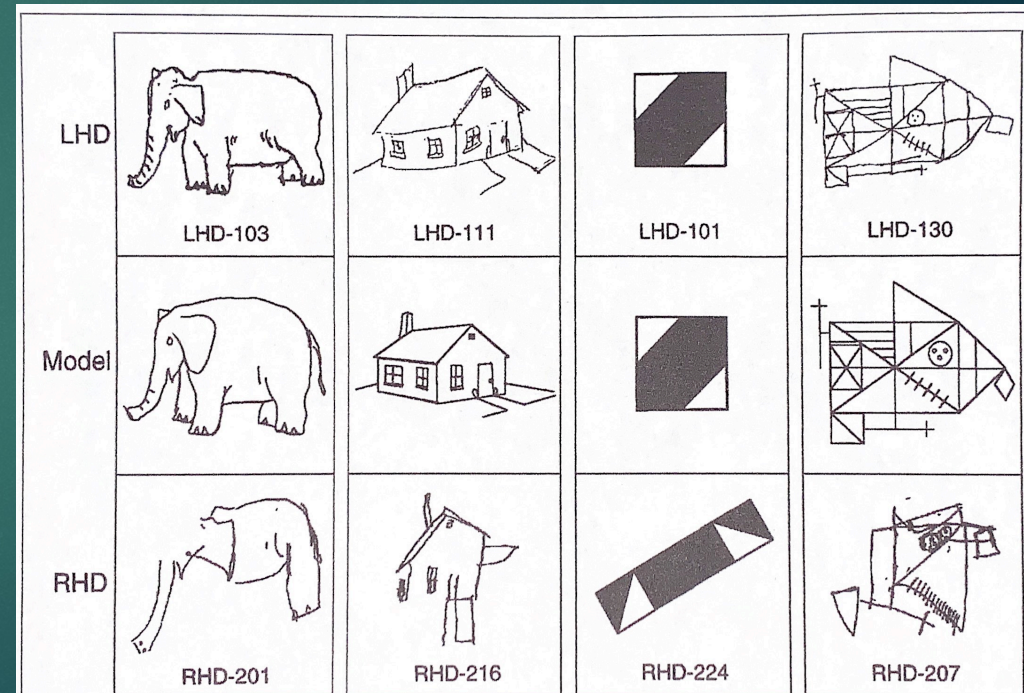


Fig. 2 Performance on spatial cognitive tasks by four aphasic LHD signers (top) and four non-aphasic RHD signers (bottom). The task in each case was to copy the model drawing in the centre panel. RHD signers show a greater impairment than LHD signers, indicating a dissociation between language and non-linguistic visuospatial functions. (Reproduced, with permission, from Ref. 15.)

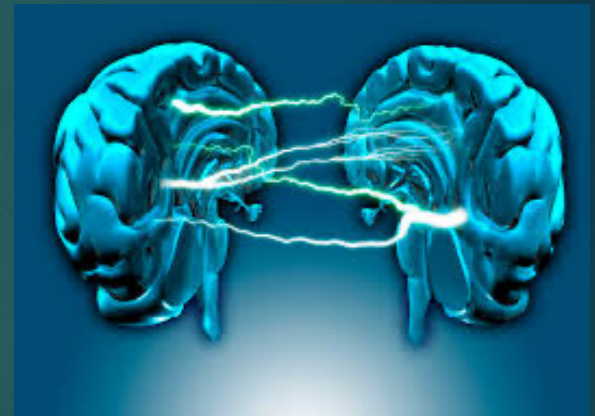GROUP STUDIES: Non-linguistic spatial cognitive assessment

CONTINUED...

- ▶ Participants: Group of left- or right-lesioned deaf signers were asked to reproduce drawings that contained hierarchically organized structure.
- ▶ Results:
 - ▶ LHD deaf subjects were significantly better at reproducing global-level (global configuration) features.
 - ▶ RHD deaf subjects were significantly better at reproducing local-level features (internal details)
 - ▶ Local-level features visuospatial deficits in LHD signers did not correlate with expressive or receptive sign language measures.
 - ▶ Thus, LHD deaf signers cannot be attributed to domain-general visuospatial deficits .

Within Hemisphere organization of signed language

- ▶ Given that sensory/motor and input/output systems are radically different in signed and spoken language
- ▶ One might expect significant reorganization of within-hemisphere areas involved in signed language processing
 - ▶ For E.g. it seems reasonable to suppose that regions involved in SL perception would be located in visual association cortex (VAC) rather than auditory association cortex (AAC).
- ▶ LIKEWISE, one might hypothesize:
 - ▶ SL production involved pre-motor regions anterior part of motor cortex rather than anterior to motor cortex for the oral articulators, where Broca's area is.
- ▶ HOWEVER, this is a difficult issue to address using the lesion approach but some preliminary data on the issue have emerged.



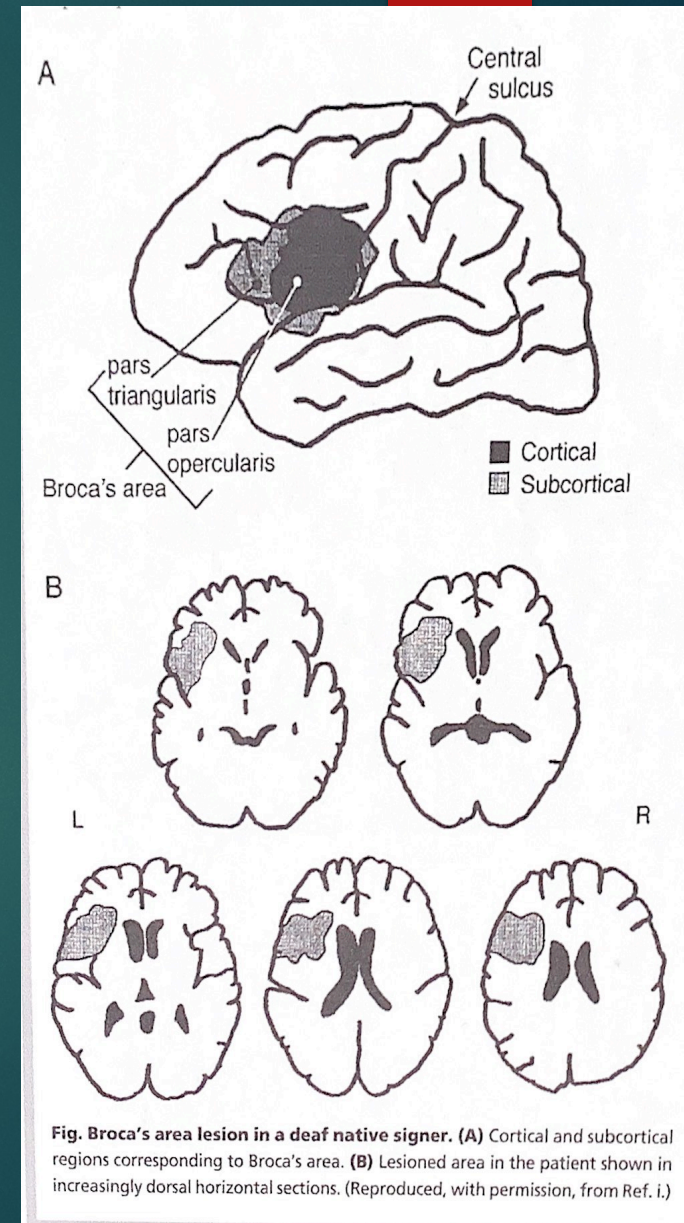
Within Hemisphere organization of signed language

CONTINUED....

- ▶ There seems to be a number of commonalities in the language deficits found in signed and spoken language.
- ▶ Aphasic symptom clusters that have been observed in deaf signers fall into classical clinical categories defined on the basis of hearing aphasics.
 - ▶ The lesions producing these patterns of deficits in LHD signers are consistent with clinical-anatomic correlations in the hearing population.
 - ▶ E.g. observation 1: there has not been a case in which lesion outside the perisylvian language zone has led to a primary aphasia.
 - ▶ E.g. observation 2: non-fluent aphasic signers have lesions involving anterior language regions.
 - ▶ Fluent aphasic signers have lesions involving posterior language regions, and Broca's area appears to play a role in ASL production (shown on next slide)

Role of Brocas area in sign language production

- ▶ Brocas area has figured prominently in hypotheses concerning the anatomy of speech production.
- ▶ “to what extent is the cerebral organization of language areas driven by the cerebral topography of the sensory-motor systems?”
 - ▶ ANS: case study of congenitally deaf, native user of ASL, who suffered an ischemic infarct involving Brocas area the inferior portion of the primary motor cortex
 - ▶ RESULTS: both similarities and diff. in the aphasia syndrome compared with that found in hearing/speaking subjects following such a lesion.
- ▶ The image to the right displays Brocas lesion area in a deaf native signer.
 - ▶ (A) shows the cortical and subcortical regions corresponding to Brocas area.
 - ▶ (B) shoes lesioned area in the patient shown in increasingly dorsal horizontal sections



Functional Dissociations (FD)

- ▶ The first 2 FD's concern the separability of SL deficits from non-linguistic processes that involve the manual modality- namely, manual praxis and gestural ability- and the 3rd examines the use of space to represent linguistic information in ASL.
 - ▶ (1) On the relation between apraxia and aphasia
 - ▶ Dissociation between motor control in the service of sign language versus in the service of non-linguistics behaviors have been reported by several authors
 - ▶ Study on **Parkinson's Disease (PD)**- exhibited disruptions in temporal organization and coordination during sign production.
 - ▶ Group of LHD signers were asked to copy non-representational manual movements using the arm ipsilateral to the lesion→ Apraxia scores did not correlate significantly with measures of SL production.
 - ▶ Data suggested that there is a significant amount of variability in some aspects of SLD that cannot be accounted for .
 - ▶ (2) Dissociation of gesture and sign language
 - ▶ CASE STUDY OF LHD SIGNER → ischemic infarct involving both anterior and posterior persylvian regions, subj. became aphasic to SL.
 - ▶ Comprehension was poor, SL production was characterized by frequent paraphasia's, and had a tendency to substitute pantomime for ASL signs.

Functional Dissociations (FD)

CONTINUED....

- ▶ (3) Use of space to communicate grammatical information versus spatial information directly.
 - ▶ ASL uses space to represent spatial information directly.
 - ▶ For e.g. describing the layout of objects in a room
 - ▶ Distinction between grammatical use of space in ASL.
 - ▶ Encoding of phonological, morphological and syntactic information described previously.
 - ▶ The use of space to encode spatial information directly in ASL discourse
 - ▶ Latter refers to → ability to use lang to communicate spatial information
 - ▶ Spoken language communicates spatial information through the use of prepositions and spatial description words → e.g. “the cup is near the left, front corner of the table”
 - ▶ You can see how the grammatical structure of such a sentence is independent of how accurate the spatial information is.
 - ▶ HOWEVER, in ASL in many cases the location of objects relative to one another is literally mapped out in (signing) space.

Functional Dissociations (FD): COMPREHENSION TASK

CONTINUED....

- ▶ (3) Use of space to communicate grammatical information versus spatial information directly.
 - ▶ PARTICIPANTS: 2 deaf native signers (1 LHD & 1 RHD)
 - ▶ TASK: Spatial task was signed description of the layout of furniture in a room and Grammatical task was signed sentences similar to “the cat chased the dog”
 - ▶ Both tasks, subjects were asked to match the signed stimulus to a picture.
 - ▶ RESULTS:
 - ▶ LHD signer was impaired on the grammatical task, but performed well on the spatial
 - ▶ RHD signer showed the reverse pattern



Neuroanatomy of sign language as revealed by functional neuroimaging

- ▶ One study addressed “Does Brocas area play a role in sign language production”.
- ▶ (1) Study: Native signers participated in a functional magnetic resonance imaging (fMRI) experiment in which they covertly produced ASL signs. RESULTS: deaf subjects did indeed show activation in Brocas area, corroborating earlier lesion data.
- ▶ (2) Study: by Neville and colleagues provided further evidence of LH language regions are activated during the perception of ASL sentences by deaf native signers.
- ▶ (3) Event related potential (ERP) work has also suggested that the within-hemisphere organization of neural systems mediating grammatical and lexical aspects of signed of signed and spoken language are quite similar.



Neuroanatomy of sign language as revealed by functional neuroimaging

Explanations

- ▶ 1. Functional imaging studies contrasted deaf subjects perceiving sign language with hearing subjects reading printed English sentences.
 - ▶ Thus the conditions differ in (1) prosodic content, a RH language function
 - ▶ (2) visual preference of a human source for linguistic signal.
- ▶ 2. The sign stimuli used in these studies may have incorporated some of the spatial description mechanisms described above, which could have driven RH systems.
- ▶ (3) A more general point is that lesion studies often target specific behaviors (e.g. naming ability, phonological processing, etc) and ignore others (e.g. discourse, prosodic abilities.)



Conclusion

- ▶ Neural organization of signed language and spatial cognition in deaf individuals has demonstrated → the same hemispheric asymmetries found in hearing, speaking individuals.
- ▶ Hemispheric organization of grammatical aspects of language is independent on modality and more specifically, unaffected by the fact that signed language involved a significant degree of visuospatial processing.
- ▶ Within-hemisphere organization of sign language hinted to some degree of similarity in the neural organization of signed and spoken language even within the left hemisphere.
- ▶ Functional dissociations has shown that deficits in processing sign language cannot be explained in terms of other domain-general deficits, i.e. manual praxis and symbolic communication
- ▶ Dissociations within aspects of sign language and between sign language and between sign language and non-linguistic spatial abilities suggest that...
 - ▶ Functional organization of cognitive systems is to some extent modular with the modules being organized with respect to representational properties of the systems (e.g. grammatical representations vs purely spatial representations)
 - ▶ Rather than physical characteristics of the stimulus (e.g. visuospatial vs temporal)



THANK YOU!!

Article: Hickok, G., Bellugi, U., & Klima, E. S. (1998). The neural organization of language: evidence from sign language aphasia. *Trends in Cognitive Sciences*, 2(4), 129-136.

